

SILK FIBROIN TECHNOLOGY

SYLKE® Adhesive Wound Closure

is the next step forward in wound closure technology.

SYLKE® was founded and developed by **M. Mark Mofid MD, FACS**, a practicing reconstructive and plastic surgeon with nearly 20 years of experience. During the early months of the COVID-19 pandemic, he focused on designing a wound closure device using silk fibroin, a material known for its strength and biocompatibility.

"I envisioned a comfortable and effective skin closure device that meets the needs of both patients and practitioners." - **M. Mark Mofid, MD, FACS**



WOUND CLOSURE WITHOUT COMPROMISE

SKU	SIZE/EA	QTY	UOM	EA/BX
SYL-WC-32-010	32 x 2.5cm	1	BX	10
SYL-WC-32-050	32 x 2.5cm	1	BX	50
SYL-WC-16-010	16 x 2.5cm	1	BX	10
SYL-WC-16-050	16 x 2.5cm	1	BX	50
SYL-WC-24-010	24 x 3.4cm	1	BX	10
SYL-WC-24-050	24 x 3.4cm	1	BX	50



PO@SYLKE.COM

+1 858-727-9553

WWW.SYLKE.COM



SYLKE® Adhesive Wound Closure is an OTC Class I, 510(k)-exempt device subject to FDA general controls; no FDA approval or clearance is implied. Product availability and indications may vary by country; see local labeling/IFU. View the full IFU at sylke.com/ifu; outcomes may vary. All trademarks are the property of their respective owners. ¹Aastroem KIM, et al. J Arthroplasty. 2025. doi:10.1016/j.arth.2025.06.071; ²Moo Young JP, et al. Arthroplast Today. 2025;33:101668. doi:10.1016/j.artd.2025.101668; ³Rouhani DS, et al. Plast Reconstr Surg. 2024. doi:10.1097/PRS.000000000011316; ⁴Rouhani DS, et al. Aesthet Surg J Open Forum. 2023. doi:10.1093/asjof/oad071 © 2025 Sylke, Inc. All Rights Reserved. MM-25-004 V1



INTENDED USE

SYLKE® Adhesive Wound Closure is a sterile, single-use silk mesh strip with pressure-sensitive adhesive. It provides a breathable, sterile barrier that supports natural healing.

Indicated for topical closure and coverage of thoroughly cleansed simple lacerations, cuts, puncture wounds, and post-surgical skin incisions (including those with subcutaneous or dermal sutures), to assist in bringing together skin edges and protecting the wound during the initial healing period. It may be used alone or as an adjunct with sutures for clean, superficial, low-tension wounds.

Contraindicated for use on infected or dirty wounds, high-tension wounds without additional support, and actively bleeding wounds. Designed to remain in place for up to 14 days while tolerating normal bathing.

32 cm x 2.5 cm



NEW

24 cm x 3.4 cm



NEW

16 cm x 2.5 cm



SILK FIBROIN WOVEN MESH

Engineered for **biocompatibility, breathability, elasticity, water resistance, and strength.**

PRESSURE-SENSITIVE ADHESIVE

Designed for **gentle, secure skin adhesion.**
Contains no cyanoacrylate adhesives.

QUICK & EASY PAPER LINER


Quick application; no glue or drying time.
Gentle removal per IFU; no solvents required.

CLINICAL DATA



- **Less hypersensitivity (0% vs 9.9%, p=0.009)**
Less application time (3.7 minutes faster; no drying time)
Less modeled total cost (\$465.91 lower per case, 2025 USD; dressing –\$327.34; OR –\$138.57; depends on institutional pricing/workflow) — total joint replacement study (n=261; vs 2-octyl cyanoacrylate mesh).¹
- **Less allergic contact dermatitis (0% vs 6.4%, p=0.018)**
— total joint replacement study (n=257; vs cyanoacrylate mesh).²
- **Less early detachment (0% vs 75% at ≤2 weeks)**
Fewer triple-point separations (9.3% vs 30.2%, p≤0.012) — plastic-surgery split-wound randomized trial (n=50; vs Steri-Strips™).³
- **Less moderate-to-severe discomfort (4% vs 64%)**
Less observable rash (0% vs 52%, both p<0.001) — plastic-surgery split-wound randomized trial (n=25; vs Dermabond Prineo™).⁴

Study outcomes are summarized from the cited publications listed on the back panel or at sylke.com/clinical and have **not been evaluated by the FDA**; inclusion here does not imply FDA review or endorsement. **Individual results vary.** See the cited publications for methods and limitations; see the IFU at sylke.com/ifu for warnings and contraindications.



Superiority of a Silk Surgical Site Wound Closure Device over Synthetic Dressings

Daniel S. Rouhani, BS¹

Navin K. Singh, MD, MBA,
MSc^{1,2}

James J. Chao, MD, PhD, MBA²

Adah Almutairi, PhD³

Mehran H. Seradj, MD⁴

Rebecca Badowski-Platz, BS⁵

Jason D. Toranto, MD²

M. Mark Mofid, MD^{1,2}

Baltimore, MD; McLean, VA; La Jolla
and San Diego, CA; and Tehran, Iran



Background: Silk fibroin is an emerging biomaterial with enhanced properties of cellular regeneration, growth, and proliferation. The use of a silk fibroin wound dressing has the potential to decrease the incidence of wound-healing complications and to improve patient outcomes compared with synthetic dressing alternatives.

Methods: A randomized, single-blind clinical trial was conducted on 50 patients who were dressed with a silk fibroin dressing on 1 side of their body and 3M Steri-Strips on the contralateral side after abdominoplasty, reduction mammoplasty, or brachioplasty procedures. Data were collected over 5 postoperative visits using photographs and an investigator-administered questionnaire to monitor erythema, skin irritation, skin discomfort, need for pharmaceutical intervention, wound dehiscence, and mechanical skin injury. A comprehensive 75-patient statistical analysis was conducted, combining the results with a previously published study comparing Dermabond Prineo with the silk dressing.

Results: A total of 20.8% of patients (10 of 48) were assessed by surgeons as having skin erythema (7 to 10) on the Steri-Strip control side, with 0% (0 of 48) on the silk dressing side ($P = 0.002$). The frequency of breast triple-point separation in 43 cases was 30.2% (13 of 43) on the Steri-Strip side and 9.3% (4 of 43) on the silk side ($P = 0.012$). A total of 75% of patients (36 of 48) had partial or total detachment of Steri-Strips, 0% (0 of 48) had total detachment of the silk dressing, and 18.8% (9 of 48) had partial detachment of the silk dressing within the first 2 weeks ($P < 0.001$).

Conclusion: A silk fibroin wound dressing significantly reduces the incidence of wound-healing complications throughout the postoperative period. (*Plast. Reconstr. Surg.* 154: 1233, 2024.)

CLINICAL QUESTION/LEVEL OF EVIDENCE: Therapeutic, II.

Clinical Relevance Statement: The adoption of a silk fibroin wound dressing into clinical practice has the potential to improve patient outcomes, decrease medical adhesive-related skin injuries, and reduce the rate of wound-healing complications.

From the ¹Johns Hopkins University School of Medicine; ²private practice; ³Pharmaceutical Chemistry, Materials Science, and Engineering and Nanoengineering, University of California, San Diego; ⁴Department of Dermatology, Shahed University; and ⁵San Diego Skin, Inc.

Received for publication September 13, 2023; accepted January 18, 2024.

This trial is registered under the name "Silk Scaffold Surgical Incision Dressing," Clinical Trials.gov identification no. NCT05508945 (<http://www.clinicaltrials.gov/ct2/show/NCT05508945>).

Copyright © 2024 The Authors. Published by Wolters Kluwer Health, Inc. on behalf of the American Society of Plastic Surgeons. This is an open-access article distributed under the terms of the Creative Commons Attribution-Non Commercial-No Derivatives License 4.0 (CCBY-NC-ND), where it is permissible to download and share the work provided it is properly cited. The work cannot be changed in any way or used commercially without permission from the journal.

DOI: 10.1097/PRS.00000000000011316

Wound closure has evolved throughout history, from the invention of sutures in ancient Egypt to the development of surgical staples in the 1900s to the modern-day innovation of skin adhesives.^{1,2} Wound dressings are often used in coordination with sutures or staples to approximate wound edges, absorb excess exudate, reduce skin tension, and provide an ideal wound-healing environment. Wound dressings include gauze, adhesive paper skin strips,

Disclosure statements are at the end of this article, following the correspondence information.

Related digital media are available in the full-text version of the article on www.PRSJournal.com.

mechanical devices, cyanoacrylate, polyester mesh systems, transparent films, silver impregnated dressings, hydrogels, and hydrocolloid dressings.³ Many of these dressings are made from synthetic compounds that have been shown to cause an array of complications known as medical adhesive–related skin injuries (MARSIs).^{4–9} Despite the variety of dressings available, the prevalence of MARSIs in the United States has been on the rise, with up to 1.5 million patients annually having serious complications attributable to surgical tapes, dressings, and adhesives.^{10,11}

MARSIs prolong the wound-healing process and lead to complications including allergic contact dermatitis, erythema, wound dehiscence, skin blisters, and mechanical skin injury from shear forces on the dermis. These complications disrupt the epidermal barrier and increase the susceptibility of the surgical wound to surgical-site infections (SSIs).^{10,12,13} A review of 69 studies published in *JAMA* in 2023¹⁴ identified that SSIs affect approximately 0.5% to 3% of all patients undergoing surgery, with hospitalization stays increasing by an average of up to 11 days. SSIs cost the US health care system more than \$10 billion annually and remain a substantial cause of morbidity, prolonged hospitalization, and death.^{14,15}

A deficiency in the Centers for Disease Control and Prevention (CDC) Surgical Care Improvement Project (SCIP) initiative has been the absence of surgical-site dressings as a measure for intervention to decrease the incidence of SSIs.^{16,17} To date, the SCIP initiative has only identified 6 known methods to reduce SSIs as supported by randomized controlled clinical trials. These include delivery of intravenous antimicrobial prophylaxis within 1 hour of incision, selection of a procedure-specific antimicrobial prophylactic agent, discontinuation of a prophylactic antimicrobial agent within 24 hours of surgery, avoidance of razors for hair removal before surgery, perioperative glycemic control, and maintenance of normothermia.^{17–19} The search for an ideal wound dressing that has the ability to reduce the prevalence of MARSIs and SSIs remains of critical importance to improve patient care and to reduce health care costs.

Silk fibroin has recently emerged as a US Food and Drug Administration–approved biomaterial of importance to the fields of regenerative science and tissue engineering.^{20,21} Silkworm silk is made of 2 distinct proteins, sericin and fibroin, with fibroin accounting for 70% of silk's molecular weight.²² Biomedical applications of silk typically require removal of the sericin coating to

minimize the immune response. Purified silk fibroin is nonimmunogenic, highly biocompatible, and noncytotoxic to human tissues.^{23,24} Silk fibroin has been used for various biomedical applications, including drug delivery, tissue engineering, wound healing, and cellular regeneration.^{22,25–27} These applications require solubilizing fibroin into a solution to cast hydrogels, films, scaffolds, and matrices.²⁸ A recent study of 25 patients compared a novel silk fibroin dressing with the 2-part 2-octyl cyanoacrylate and polyester mesh system (Dermabond Prineo).²⁹ This was the first randomized controlled trial studying the effects of a woven silk fibroin dressing over surgically cut incisions. A significant improvement was found in patient comfort, decreased skin irritation, and a reduction of MARSIs, including allergic contact dermatitis (24% Dermabond Prineo versus 0% silk dressing; $P < 0.001$). No adverse events were found with the silk fibroin wound dressing.

We hypothesize that because of the high biocompatibility, low cytotoxicity, and native regenerative attributes of silk fibroin, the use of a silk fibroin wound dressing will decrease the incidence of MARSIs in surgically cut and closed wounds.

PATIENTS AND METHODS

Study Design

A randomized, single-blind, institutional review board (IRB)–approved (Western IRB) clinical trial was conducted to compare a silk fibroin wound dressing with Steri-Strips (3M) in 50 patients. This study used a protocol similar to a previously published clinical trial that compared the silk fibroin dressing with Dermabond Prineo in 25 patients.²⁹ The current study also includes a cumulative statistical analysis of all 75 combined patients to determine the safety and efficacy of the silk fibroin wound dressing over both adhesive paper tape and polyester mesh cyanoacrylate wound dressings.

The date range of this study was from August 22, 2022, to June 21, 2023. Fifty patients consented to the study and underwent abdominoplasty, belt lipectomy, brachioplasty, mastopexy, and reduction mammoplasty procedures. Three patients underwent combined procedures and received the randomized application of control and experimental dressings to each surgical site. Follow-up scores in these patients were averaged in statistical calculations. After incisions were closed, a 1:1 computer-randomized generator was used to select the side for application of the experimental silk dressing to control for surgeon

operational bias. Sutured surgical incisions were dressed with the experimental silk wound dressing on the ipsilateral side and Steri-Strips on the contralateral control side, and thus, each patient served as their own internal control. Patients were blinded in the study and were not told which side was the experimental or control side. The physicians and clinical trial staff refrained from using dressing names and referred to each side as the left or right side of the patient to maintain patient blinding during follow-up appointments.

Inclusion and Exclusion Criteria

All eligible patients signed written consent forms in accordance with the ethical standards of the Declaration of Helsinki and satisfied the following inclusion criteria: 18 years of age or older, fluency in the English language, cognitive ability to consent, and preoperative surgical clearance from a primary care physician. Study participants were excluded for the following: history of an autoimmune disorder, diabetes, malignancy, tobacco use, or a known allergy to Steri-Strips or natural silk. Age, weight, height, body mass index, and race and ethnicity were recorded.

Interventions

Experimental silk wound dressings were created by laminating sterile Seri Scaffold (Sofregan Medical) 10 × 25-cm sheets with a pressure-sensitive acrylic adhesive (dermaFLEX; Flexcon) and a paper backing. Sheets were then cut into 2.5 × 25-cm strips, rolled into self-sealable autoclave pouches, and resterilized with ethylene oxide for 24 hours. Control dressings consisted of 12.5 × 2.5-cm Steri-Strips.

Outcomes

The primary outcome was the incidence of MARSIs as determined by a custom prepared investigator-administered questionnaire to assess the occurrence of skin discomfort, itching or irritation, and erythema. The questionnaire was given at clinical observation points on days 1 through 3 and at weeks 1, 2, 4, and 6. Patients were prompted to self-report symptoms on a scale of 0 to 10, where 0 reflected no discomfort or itching and 10 reflected severe or intolerable skin discomfort or itching. Photographs were taken at each visit and investigator observations were made about the presence of erythema on a scale of 0 to 10, where 0 reflected the absence of erythema and 10 reflected severe erythema. Scores were categorized as 0 to 3, indicating no to mild reaction; 4 to 6, indicating a moderate

reaction; or 7 to 10, indicating a severe reaction. Measures for the patient-administered questionnaire and the assessment of erythema were created with the guidance of the Joint Task Force on Practice Parameters for Allergy and Immunology for Contact Dermatitis.³⁰

Secondary outcomes included postoperative incisional separation or wound dehiscence, the need for topical steroids to treat complications of allergic contact dermatitis, and the need for oral or intravenous antibiotics to treat cellulitis or presumptive infection. The time needed for removal was recorded in seconds to remove each wound dressing. In accordance with manufacturer recommendations, both dressings were removed at 14 days. Premature detachment of the dressing before the anticipated removal was recorded for both sides. Early removal of the surgical site dressing before postoperative day 14 was performed by the treating physician because of rash, infection, or excess wound drainage. If complications were localized to 1 side of the incision or 1 breast or arm, the wound dressing on the unaffected side was not removed until postoperative day 14, as scheduled. Data were collected and managed in an Excel spreadsheet (Microsoft Corp.).

Sample Size

The sample size calculation was justified for 50 patients. Because each patient received both treatments, the calculated sample size was 100 (50 silk dressing and 50 Steri-Strips). This was based on the anticipated incidence of total MARSIs of 16.7% on the Steri-Strip control side and an incidence of 1% on the silk wound dressing side with a power of 80% and an alpha level of 0.05. A 2-tailed *t* test was used. The incidence of MARSIs on the Steri-Strip control side was based on previous literature as well as the previous experience of the authors to select an anticipated value of reaction.^{10,29,31} One previous study that compared the experimental silk dressing with Dermabond Prineo in 25 patients revealed no MARSIs (0 of 25) with the silk dressing.²⁹

Statistical Analysis

Statistical analyses were performed using SPSS (SPSS Inc.) version 16.0 software with the null hypothesis that the performance of the hypoallergenic silk fibroin dressing is equivalent to the performance of Dermabond Prineo or Steri-Strips. The alternative hypothesis is that the performance of the silk dressing is different compared with the performance of Dermabond Prineo or Steri-Strips in wound management of

Table 1. Demographic Data

Characteristics	Mean ± SD	Median	Interquartile Range	Mode	Minimum	Maximum
Age, yrs	43.6 ± 16.0	44.5	29	24.0 ^a	19	76
Body mass index	28.5 ± 5.3	27.4	8.2	23.6 ^a	20.1	45.5
Weight, lb	170.2 ± 35.4	160	49.2	150	110	265

^aMultiple modes exist. The smallest value is shown.

Table 2. Procedure Types (48 Cases)

Procedure	Frequency (%)
Abdominoplasty	5 (10.4)
Body lift	1 (2.1)
Brachioplasty	2 (4.2)
Brachioplasty, mastopexy, abdominoplasty	1 (2.1)
Breast reduction	25 (52.1)
Breast reduction/abdominoplasty	1 (2.1)
Capsulectomy/mastopexy	1 (2.1)
Lower body lift/inner thigh lift	1 (2.1)
Mastopexy	10 (20.8)
Mastopexy/abdominoplasty	1 (2.1)
Total	48 (100.0)

breast lift or reduction, abdominoplasty or body lift, and brachioplasty.

To compare the frequency of nominal variables, a nonparametric related sample McNemar test was applied to 2×2 tables. The paired *t* test was used for continuous variables with normal distributions. Wilcoxon signed rank test was conducted to assess any difference in mean ranks when normality assumption was not demonstrated. Kolmogorov-Simonov and Shapiro-Wilk tests were used to assess normal distribution.

RESULTS

A total of 50 patients were randomized between August 11, 2022, and July 30, 2023. Two

patients were excluded from the study: 1 because of a serious motor vehicle accident and the second because of an unexpected breast cancer diagnosis in the pathology specimen. The remaining 48 participants (median age, 44.5 years [interquartile range (IQR), 29]; median body mass index, 27.4 [IQR, 8.2]; median weight [lbs], 160 [IQR, 49.2]; 48 biologic women) were assessed to calculate primary and secondary outcome measures. The most common procedure in the study group was breast reduction (52%), with the second most prevalent being mastopexy procedures (20.8%) (Tables 1 and 2).

A total of 10.4% of patients (5 of 48) developed visible blisters with Steri-Strips; none (0 of 48) developed skin blisters on the experimental silk wound dressing side ($P=0.063$) (Figs. 1 through 3). (See Figure, Supplemental Digital Content 1, which shows a photograph of epidermal barrier disruption as a result of skin shearing and blisters with Steri-Strips. The patient is a 62-year-old woman, day 5 after reduction mammoplasty, <http://links.lww.com/PRS/H172>.) The frequency of breast triple-point separation in 43 cases was 30.2% (13 of 43) on the Steri-Strip side and 9.3% (4 of 43) on the silk dressing side ($P=0.012$) (Figs. 4 through 6). A total of 20.8% of patients (10 of 48) required early removal of Steri-Strips because of underlying complications; none (0 of 48)

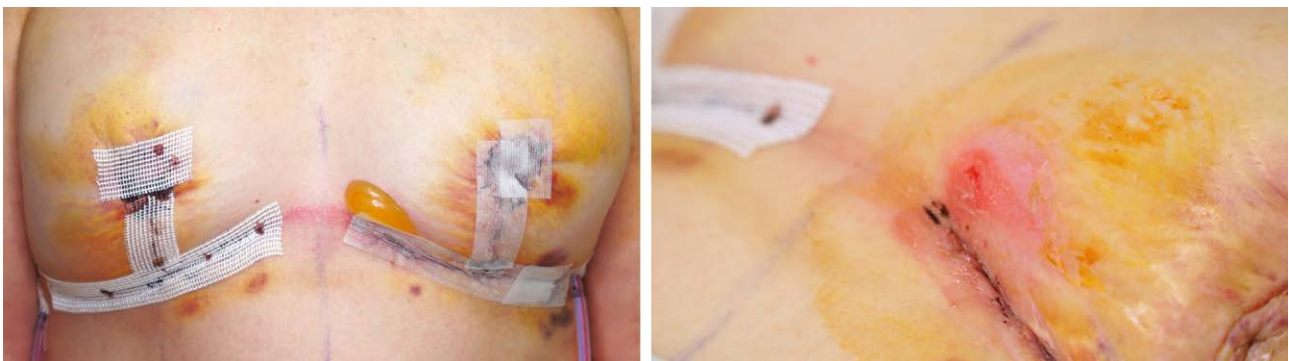

Fig. 1. A 70-year-old woman is shown on day 4 after mastopexy surgery. (Left) The patient's right breast was dressed with the experimental silk wound dressing and showed no signs of blistering. The patient's left breast was dressed with Steri-Strips, causing a large fluid-filled vesicle as a result of shear forces exerted on the dermis. (Right) The blister was unroofed, resulting in disruption of the epidermal barrier.

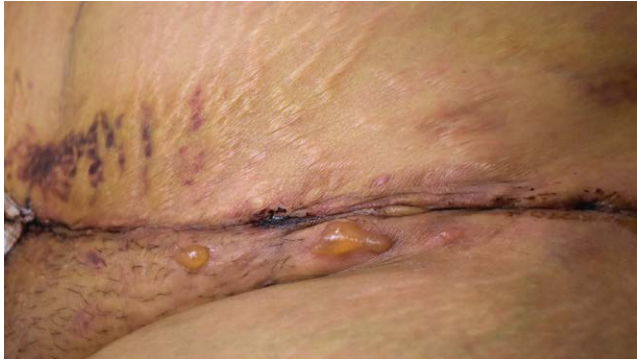

Fig. 2. A 36-year-old woman is shown on day 5 after abdominoplasty surgery. The patient developed 3 blisters on her left abdomen dressed with Steri-Strips. The patient's right abdomen was dressed with the experimental silk wound dressing and had no blisters.

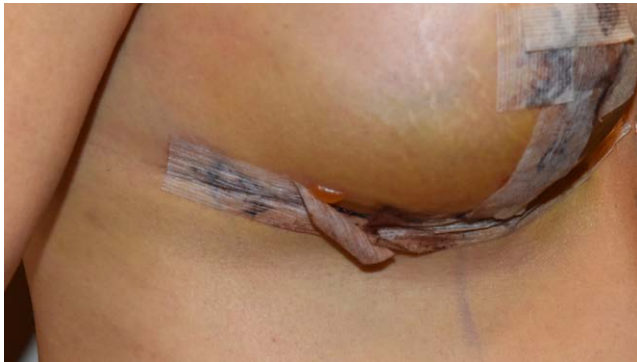

Fig. 3. A 42-year-old woman is shown on day 4 after mastopexy surgery. The patient presented with a blister on her right breast dressed with Steri-Strips. The patient's left breast was dressed with the silk wound dressing and had no blisters.

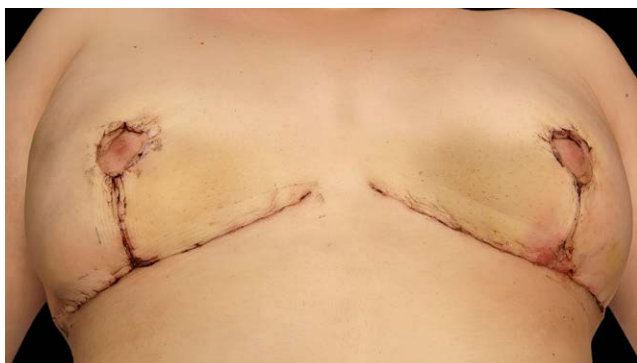

Fig. 4. A 26-year-old woman is shown on day 15 after reduction mammoplasty surgery. The patient presented with inflammation, erythema, and pain at the triple point on the left breast dressed with Steri-Strips. The patient's right breast was dressed with the experimental silk wound dressing and showed no signs of wound-healing complications.

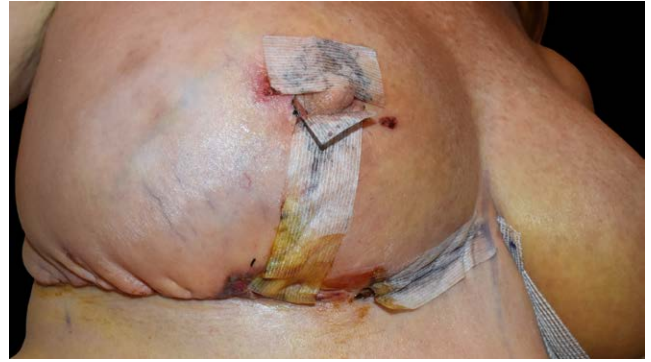

Fig. 5. A 51-year-old woman is shown on day 7 after reduction mammoplasty surgery. The patient presented with triple-point separation, copious wound exudate, inflammation, and discomfort on the right breast dressed with Steri-Strips. The patient also presented with 2 blisters surrounding the right areola. The patient's left breast was dressed with the silk wound dressing and experienced no wound-healing complications.

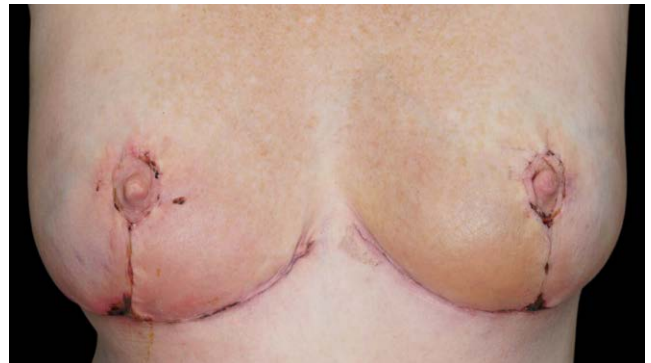

Fig. 6. A 51-year-old woman is shown on day 14 after reduction mammoplasty surgery. Right inferior pole erythema, discomfort, and triple-point separation on the side dressed with Steri-Strips were noted. There was quiescent wound healing at the inferior pole of the left breast dressed with the experimental silk wound dressing.

required early removal of the silk dressing. A total of 75% of patients (36 of 48) had partial or total detachment of the Steri-Strip dressing during normal shower or bathing routines, and 18.8% of patients (9 of 48) had partial detachment of the silk dressing within the first 2 weeks ($P < 0.001$). The need for pharmaceutical intervention including topical or oral antibiotics for the treatment of complications on the control Steri-Strip side was 45.8% (22 of 48), versus none (0 of 48) on the experimental silk dressing side. (See Table, Supplemental Digital Content 2, which shows secondary outcome measures reported in the study for the silk dressing versus Steri-Strips

Table 3. Frequency of Discomfort, Irritation, and Erythema in the Silk Dressing and Steri-Strips (48 Patients)

Visit	Frequency of Moderate to Severe Reaction (%)	<i>P</i> ^a	Frequency of Any Reaction (%) ^b	<i>P</i> ^a	Frequency of Severe Reaction (%) ^b	<i>P</i> ^a
First follow-up visit (1 to 4 days after procedure, <i>n</i> = 45)						
Silk skin discomfort	0 (0)	0.004 ^c	6 (13.3)	0.021 ^c	0 (0)	0.125
Steri-Strip skin discomfort	9 (20)		14 (31.1)		4 (8.9)	
Silk irritation or itching	0 (0)	0.016 ^c	1 (2.2)	0.004 ^c	0 (0)	0.250
Steri-Strip irritation or itching	7 (15.6)		10 (22.2)		3 (6.7)	
Silk rash	0 (0)	0.063	2 (4.4)	0.004 ^c	0 (0)	0.500
Steri-Strip rash	5 (11.1)		11 (24.4)		2 (4.4)	
Second follow-up visit (1 wk after procedure, <i>n</i> = 46)						
Silk skin discomfort	2 (4.3)	0.002 ^c	8 (17.4)	0.002 ^c	0 (0)	0.250
Steri-Strip skin discomfort	14 (30.4)		20 (43.5)		3 (6.5)	
Silk irritation or itching	1 (2.2)	0.002 ^c	7 (15.2)	0.002 ^c	0 (0)	0.125
Steri-Strip irritation or itching	11 (23.9)		19 (41.3)		4 (8.7)	
Silk rash	0 (0)	0.004	0 (0)	<0.001 ^c	0 (0)	1.000
Steri-Strip rash	9 (19.6)		14 (30.4)		1 (30.4)	
Third follow-up visit (2 wks after procedure, <i>n</i> = 45)						
Silk skin discomfort	0 (0)	<0.001 ^c	6 (13.3)	<0.001 ^c	0 (0)	0.063
Steri-Strip skin discomfort	14 (31.1)		25 (55.6)		5 (11.1)	
Silk irritation or itching	1 (2.2)	0.004 ^c	6 (13.3)	<0.001 ^c	0 (0)	0.500
Steri-Strip irritation or itching	10 (22.2)		18 (40)		2 (4.4)	
Silk rash	1 (2.2)	<0.001 ^c	4 (8.9)	<0.001 ^c	0 (0)	0.063
Steri-Strip rash	17 (37.8)		23 (51.1)		5 (11.1)	
Fourth follow-up visit (4 wks after procedure, <i>n</i> = 42)						
Silk skin discomfort	0 (0)	0.250	2 (4.8)	0.063	0 (0)	0.250
Steri-Strip skin discomfort	3 (7.1)		7 (16.7)		3 (7.1)	
Silk irritation or itching	0 (0)	0.063	2 (4.8)	0.031 ^c	0 (0)	0.500
Steri-Strip irritation or itching	5 (11.9)		8 (19)		2 (4.8)	
Silk rash	0 (0)	0.004 ^c	1 (2.1)	0.001 ^c	0 (0)	0.063
Steri-Strip rash	9 (21.4)		12 (28.6)		5 (11.9)	
Fifth follow-up visit (6–8 wk after procedure, <i>n</i> = 40)						
Silk skin discomfort	0 (0)	1.000	1 (2.5)	1.000	0 (0)	— ^d
Steri-Strip skin discomfort	1 (2.5)		1 (2.5)		0 (0)	
Silk irritation or itching	0 (0)	1.000	1 (2.5)	0.250	0 (0)	— ^d
Steri-Strip irritation or itching	1 (2.5)		4 (10)		0 (0)	
Silk rash	0 (0)	0.008 ^c	1 (2.5)	0.008	0 (0)	0.250
Steri-strip rash	8 (20)		9 (22.5)		3 (7.5)	
Overall (the highest scores recorded in all 5 visits, <i>n</i> = 48)						
Silk skin discomfort	2 (4.2)	<0.001 ^c	18 (37.5)	<0.001 ^c	0 (0)	0.001 ^c
Steri-Strip skin discomfort	26 (54.2)		35 (72.9)		11 (22.9)	
Silk irritation or itching	2 (4.2)	<0.001 ^c	14 (29.2)	<0.001 ^c	0 (0)	0.002 ^c
Steri-Strip irritation or itching	25 (52.1)		32 (66.7)		10 (20.8)	
Silk rash	1 (2.1)	<0.001 ^c	8 (16.7)	<0.001 ^c	0 (0)	0.002 ^c
Steri-Strip rash	26 (54.2)		35 (72.9)		10 (20.8)	

^aRelated samples McNemar test. Exact significance is displayed.

^bFrequency of any recorded score except 0 (no reactions excluded).

^cStatistically significant.

^dThe test could not be executed.

[*n* = 48]. This study followed the CDC’s SCIP initiative guidelines for antibiotic cessation 24 hours after surgery. Need for pharmaceutical intervention for early signs of cellulitis, blistering, or severe

wound dehiscence are reported. A significant reduction in triple-point separation is also shown, which is supported by photographic documentation of each case. Early removal of Steri-Strips was

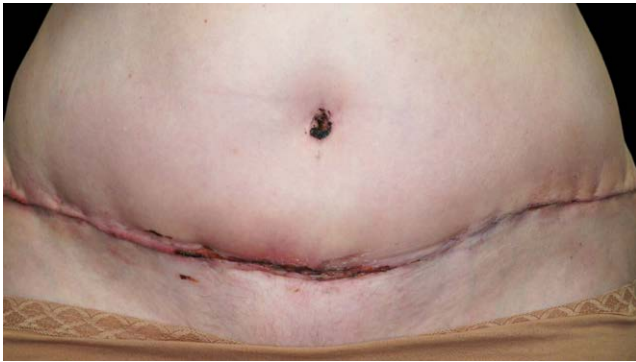

Fig. 7. A 51-year-old woman is shown on day 14 after abdominoplasty surgery. Erythema and skin discomfort were noted on the right side dressed with Steri-Strips. The left abdomen covered by the silk dressing showed no signs of wound-healing complications.

due to blistering or early signs of cellulitis, <http://links.lww.com/PRS/H173>.)

A total of 22.9% of patients (11 of 48) characterized the severity of skin discomfort as severe (7 to 10) on the Steri-Strip control side and none (0 of 48) on the experimental silk dressing side ($P = 0.001$). A total of 54.2% of patients (26 of 48) characterized the severity of skin discomfort as moderate to severe (4 to 10) on the Steri-Strip control side and 4.2% (2 of 48) on the silk dressing side ($P < 0.001$). Individual calculations were completed on each of the 5 follow-up appointments and are presented in Table 3 along with an overall value determined by the highest scores recorded in all visits. The most significant differences between the 2 groups were seen 2 weeks after the procedure.

A total of 20.8% of patients (10 of 48) characterized the severity of skin irritation or itching as severe (7 to 10) on the Steri-Strip control side and none (0 of 48) on the experimental silk dressing side ($P = 0.002$). A total of 52.1% of patients (25 of 48) characterized the severity of skin irritation or itching as moderate to severe (4 to 10) on the Steri-Strip control side and 4.2% (2 of 48) on the silk dressing side ($P < 0.001$) (Table 3).

A total of 20.8% of patients (10 of 48) were assessed by surgeons as having severe skin erythema (7 to 10) on the Steri-Strip control side and none (0 of 48) on the experimental silk dressing side ($P = 0.002$). A total of 52.1% of patients (25 of 48) were found to have moderate to severe skin erythema (4 to 10) on the Steri-Strip control side and 4.2% (2 of 48) on the silk dressing side ($P < 0.001$) (Table 3 and Fig. 7). For the 48 patients, the frequency of moderate to severe skin discomfort, irritation or itching, and erythema over all follow-up appointments during the clinical trial are presented in Figure 8. Differences in scar outcomes are presented in Figure 9.

A collective analysis was completed that combined data from a previous study of 25 patients (comparison of a silk fibroin dressing versus Dermabond Prineo) with our current study of 48 patients (comparison of a silk fibroin dressing versus Steri-Strips) to determine the safety and efficacy of the silk dressing in a total of 73 patients. For the collective 73 patients, the silk dressing showed a statistically significant decrease in the rates of moderate to severe discomfort (57.5% control versus 4.1% silk [$P < 0.001$]), irritation or itching (45.2% control versus 5.5% silk [$P < 0.001$]), and erythema (53.4% control versus 1.4%

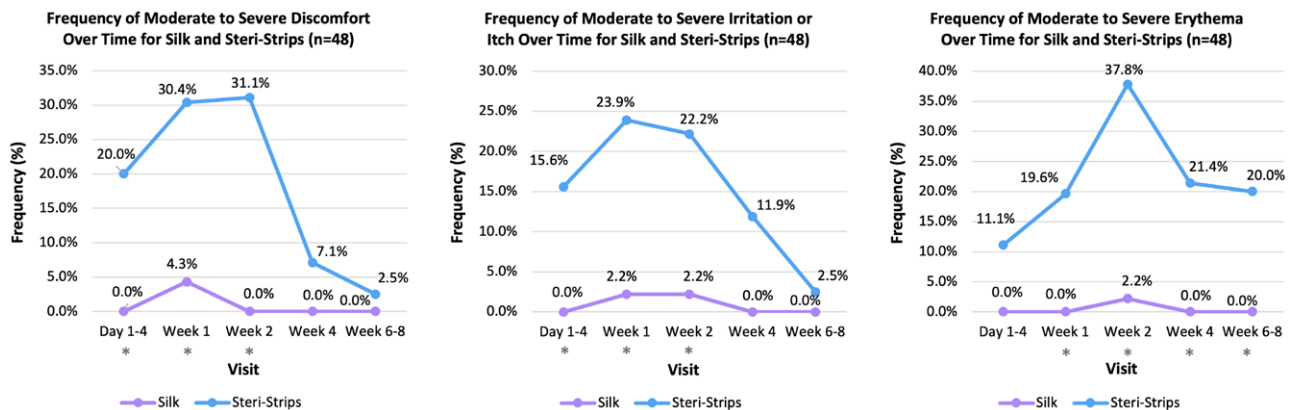


Fig. 8. Frequency of moderate to severe discomfort (left), irritation or itching (center), and erythema (right) over time for the silk wound dressing and Steri-Strips (48 patients). Frequency of discomfort and irritation reached maximum values between weeks 1 and 2; the frequency of erythema reached maximum values at week 2. *Statistical significance between experimental and control groups.

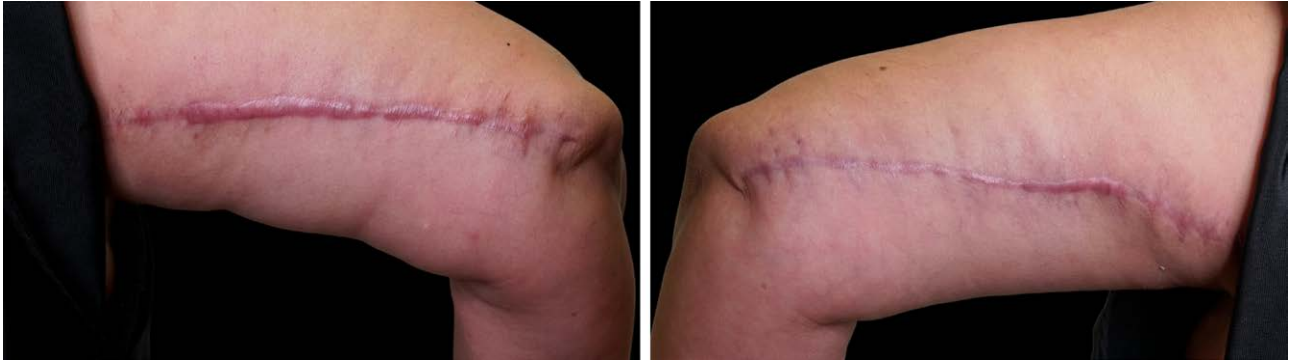

Fig. 9. A 56-year-old woman is shown 5 months after brachioplasty surgery. (Left) The patient's right arm was dressed with Steri-Strips. The hypertrophic scar is wider and displays more pronounced neovascular changes compared with the patient's left arm (right), which was dressed with the silk dressing.

silk [$P < 0.001$] (Table 4). For all 73 patients, the frequency of moderate to severe discomfort, irritation, itching, and erythema throughout all 5 individual follow-up appointments are presented in Figure 10. Additional information and the types of procedures are shown in Supplemental Digital Content 3 and 4. (See Table, Supplemental Digital Content 3, which shows collective distribution of demographic information in the study group containing analysis of both Dermabond Prineo [$n = 25$] and Steri-Strips [$n = 48$] in comparison with the silk dressing [$n = 73$], <http://links.lww.com/PRS/H174>. See Table, Supplemental Digital Content 4, which shows collective distribution of procedures in the study group containing analysis of both Dermabond Prineo [$n = 25$] and Steri-Strips [$n = 48$] in comparison with the silk dressing [$n = 73$], <http://links.lww.com/PRS/H175>.)

DISCUSSION

This study demonstrates pronounced statistically significant differences in wound-healing outcomes between the experimental silk fibroin wound dressing and Steri-Strips during the perioperative period. The silk wound dressing increases patient comfort and decreases skin irritation, erythema, and wound dehiscence. Steri-Strips are made from rayon, a semisynthetic fiber manufactured from cellulose, regarded as a low-cost material in the textile industry.³² The production of rayon uses a hazardous and controversial chemical process that raises many environmental and ethical concerns.³³ Unlike silk fibroin, which is a natural and regenerative organic compound, rayon lacks many of the ideal characteristics for optimal wound healing.³⁴ The stable approximation of wound edges over contoured and irregular surfaces, in

addition to fibroin's natural properties, may also explain the differences seen in scar outcomes shown in Figure 9.

The silk fibroin wound dressing is a mesh that allows for oxygen exchange at the surgical site and wound exudate egress through fenestrations, which are properties that have been shown to improve wound-healing outcomes.³⁵ The innate flexibility of the experimental silk wound dressing allows for the even distribution of shear forces that prevents the formation of blisters.³⁶ Nonwoven rayon is an inelastic material that fails to accommodate for changes in skin tension, post-surgical swelling, and motion at the surgical site. Our study documented 5 cases of skin blisters with Steri-Strips and no cases of blisters with the silk wound dressing.

The innate biomechanical characteristics of rayon may also contribute to the high rates of dressing detachment with Steri-Strips. Rayon is a hydrophilic material and experiences a degradation of skin adhesion over time because of the absorption of wound exudate and water from normal bathing routines.³⁷ Silk fibroin, however, is hydrophobic, and allows for stable dressing adherence throughout the 2-week period.³⁸ Our study has shown that wound dressing choice plays a significant role in reducing postoperative wound-healing complications. In reduction mammoplasty procedures, complication rates have been reported to range from 11.4%³⁹ to 77%,⁴⁰ with a common range falling between 43% and 53%, similar to our study.^{41,42} The most cited complication is delayed wound healing as a result of wound dehiscence at the triple point. Given the 75% rate of premature detachment of Steri-Strips within the first 2 postoperative weeks, Steri-Strips offer minimal support to mitigate this common complication. Our study followed the CDC's SCIP

Table 4. Frequency of Discomfort, Irritation, and Erythema in the Silk Dressing, Dermabond Prineo, or Steri-Strips (73 Patients)

Visit	Frequency of Moderate to Severe Reaction (%)	<i>P</i> ^a	Frequency of Any Reaction (%) ^b	<i>P</i> ^a	Frequency of Severe Reaction (%) ^b	<i>P</i> ^a
First follow-up visit (1 to 4 days after procedure, <i>n</i> = 70)						
Silk skin discomfort	0 (0)	<0.001 ^c	6 (8.6)	<0.001 ^c	0 (0)	0.016 ^c
Prineo or Steri-Strip skin discomfort	16 (22.9)		23 (32.9)		7 (10)	
Silk irritation or itching	0 (0)	0.004 ^c	1 (1.4)	<0.001 ^c	0 (0)	0.125
Prineo or Steri-Strip irritation or itching	9 (12.9)		17 (24.3)		4 (5.7)	
Silk rash	0 (0)	0.016 ^c	2 (2.9)	<0.001 ^c	0 (0)	0.250
Prineo or Steri-Strip rash	7 (10)		20 (28.6)		3 (4.3)	
Second follow-up visit (1 wk after procedure, <i>n</i> = 71)						
Silk skin discomfort	2 (2.8)	<0.001 ^c	9 (12.7)	<0.001 ^c	0 (0)	0.031
Prineo or Steri-Strip skin discomfort	19 (26.8)		30 (42.3)		6 (8.5)	
Silk irritation or itching	2 (2.8)	<0.001 ^c	9 (12.7)	<0.001 ^c	0 (0)	0.031
Prineo or Steri-Strip irritation or itching	14 (19.7)		27 (38)		6 (8.5)	
Silk rash	0 (0)	<0.001 ^c	0 (0)	<0.001 ^c	0 (0)	0.125
Prineo or Steri-Strip rash	12 (16.9)		19 (26.8)		4 (26.8)	
Third follow-up visit (2 wks after procedure, <i>n</i> = 66)						
Silk skin discomfort	1 (1.4)	<0.001 ^c	8 (11.4)	<0.001 ^c	0 (0)	0.002
Prineo or Steri-Strip skin discomfort	22 (31.4)		37 (52.9)		10 (14.3)	
Silk irritation or itching	2 (2.9)	<0.001 ^c	8 (11.4)	<0.001 ^c	0 (0)	0.125
Prineo or Steri-Strip irritation or itching	15 (21.4)		29 (41.4)		4 (5.7)	
Silk rash	1 (1.4)	<0.001 ^c	7 (10)	<0.001 ^c	0 (0)	0.004
Prineo or Steri-Strip rash	27 (38.6)		36 (52.2)		9 (12.9)	
Fourth follow-up visit (4 wks after procedure, <i>n</i> = 67)						
Silk skin discomfort	0 (0)	0.004 ^c	4 (6)	<0.001 ^c	0 (0)	0.125
Prineo or Steri-Strip skin discomfort	9 (13.4)		16 (23.9)		4 (6)	
Silk irritation or itching	1 (1.5)	0.125	7 (10.4)	0.008 ^c	0 (0)	0.500
Prineo or Steri-Strip irritation or itching	6 (9)		15 (22.4)		2 (3)	
Silk rash	1 (1.5)	0.002 ^c	2 (3)	<0.001 ^c	0 (0)	0.063
Prineo or Steri-Strip rash	11 (16.4)		18 (27.3)		5 (7.6)	
Fifth follow-up visit (6–8 wks after procedure, <i>n</i> = 65)						
Silk skin discomfort	0 (0)	0.500	1 (1.5)	0.625	0 (0)	— ^d
Prineo or Steri-Strip skin discomfort	2 (3.1)		3 (4.6)		0 (0)	
Silk irritation or itching	0 (0)	1.000	2 (3.1)	0.031 ^c	0 (0)	— ^d
Prineo or Steri-Strip irritation or itching	1 (1.5)		8 (12.3)		0 (0)	
Silk rash (64 cases)	1 (1.5)	0.004 ^c	1 (1.5)	0.001	0 (0)	0.250
Prineo or Steri-Strip rash (64 cases)	10 (15.4)		12 (118.8)		3 (4.7)	
Overall (the highest scores recorded in all 5 visits, <i>n</i> = 73)						
Silk skin discomfort	3 (4.1)	<0.001 ^c	22 (30.1)	<0.001 ^c	0 (0)	<0.001 ^c
Prineo or Steri-Strip skin discomfort	42 (57.5)		53 (72.6)		20 (27.4)	
Silk irritation or itching	4 (5.5)	<0.001 ^c	21 (28.8)	<0.001 ^c	0 (0)	<0.001 ^c
Prineo or Steri-Strip irritation or itching	33 (45.2)		51 (69.9)		14 (19.2)	
Silk rash	1 (1.4)	<0.001 ^c	13 (17.8)	<0.001 ^c	0 (0)	<0.001 ^c
Prineo or Steri-Strip rash	39 (53.4)		54 (74)		16 (19.2)	

^aRelated samples McNemar test. Exact significance is displayed.

^bFrequency of any recorded score except 0 (no reactions excluded).

^cStatistically significant.

^dThe test could not be executed.

initiative guidelines for postoperative antibiotic cessation 24 hours after surgery. Wound-healing complications were treated in the early stages to prevent the need for inpatient hospitalization or surgical débridement. Topical mupirocin 2%

ointment twice per day and oral antibiotics were prescribed at early signs of cellulitis in association with low-grade temperatures, discolored or purulent wound drainage, severe wound dehiscence, or triple-point separation.

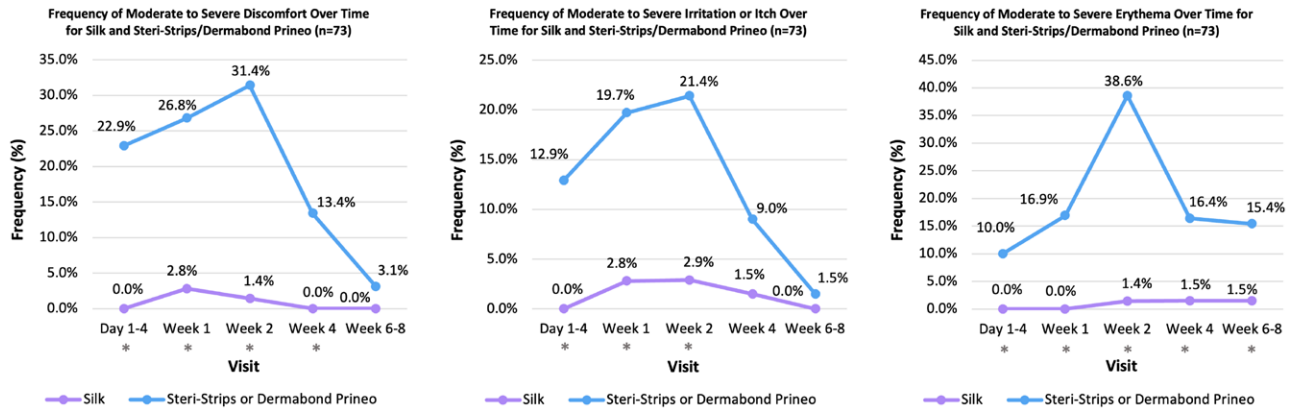


Fig. 10. Collective analysis of 73 patients documenting the frequency of moderate to severe discomfort (*left*), irritation or itching (*center*), and erythema (*right*) over time for the experimental silk wound dressing and control Steri-Strips or Dermabond Prineo. The frequency of discomfort, irritation, and erythema reached maximum values at week 2. In 73 patients, the silk wound dressing was applied to the experimental side. In 48 patients, Steri-Strips were applied to the control side, and in 25 patients, Dermabond Prineo was applied to the control side. *Statistical significance between experimental and control groups.

Silk fibroin's unique properties, including its high biocompatibility, low immunogenicity, high mechanical strength, flexibility, regenerative attributes, and hemostatic characteristics, have made it a versatile material for various biomedical applications.^{22,26,28} This is the second IRB-approved clinical trial to study a woven silk fibroin dressing for wound healing. Other trials have studied silk fibroin in animal and in vitro models, offering limited yet promising results for the clinical applications of silk fibroin.^{43–45} Zhang et al.⁴⁶ conducted a randomized, single-blind clinical trial on full-thickness skin defects in 71 patients, to compare a pure silk fibroin film with Sidaiyi (a silk fibroin sponge–silicone 2-layered scaffold). This study concluded that a silk fibroin film significantly accelerates wound healing ($P=0.015$) and had no adverse events compared with the control dressing. Park et al.⁴⁷ studied silk fibroin in vitro and in vivo using fibroblast cell lines from mice and rats. The results showed increased expression of nuclear factor kappa B signaling pathway genes during silk fibroin treatment. This molecular pathway is essential in wound healing and affects cell proliferation, adhesion, and inflammation, and elimination of reactive oxygen species.^{22,48,49} Further studies have also quantified the positive effects of silk fibroin on treating burns and diabetic wounds.^{50–53}

The main limitation of this study was that only 2 control dressings were studied in comparison with the experimental silk wound dressing. The 73-patient analysis totaled 146 experimental sites (73 silk fibroin, 48 Steri-Strips, and 25 Dermabond Prineo). It would be helpful to compare the silk dressing with a broader array of surgical-site

wound dressings and closure devices. The application of the silk wound dressing across various medical specialties, including orthopedic and cardiac surgery, gynecology, and laceration repair, would improve the reporting of MARSIs and expand the generalizability of the study. This study involved multiple procedures, including reduction mammoplasties, abdominoplasties, and brachioplasties; however, more than 70% of cases involved breast procedures. This emphasizes a necessity for further research to broaden the application of the silk dressing across various surgical procedures. Because of the high rates of Steri-Strip detachment found in this study within the first 2 postoperative weeks, the conclusions may be limited inasmuch as the high rates of cellulitis and other complications seen with Steri-Strips may be related to the absence of a dressing or wound closure device rather than the Steri-Strip itself.

CONCLUSIONS

The experimental silk wound dressing has been shown to improve patient outcomes and comfort while decreasing the incidence of MARSIs and wound-healing complications. (See **Video [online]**, in which author Daniel S. Rouhani discusses silk scaffold wound dressing and shares insights into the study's conclusions and clinical relevance.) The beneficial properties of a woven silk fibroin wound dressing include high biocompatibility, nonallergenicity, ease of application and removal, oxygen permeability across the healing surgical site, wound exudate egress, flexibility, mechanical strength, promotion of skin edge

detensioning, and minimization of shear forces at the level of the dermis.^{29,46} This study presents an innovative alternative for surgical-site wound dressings through the modern reinvention of one of the oldest biomaterials known to man: silk.

M. Mark Mofid, MD
4150 Regents Park Row, Suite 300
La Jolla, CA 92037
drmfid@drmfid.com
Instagram: @drmarkmofid

DISCLOSURE

Dr. Mofid has a financial interest in US patents 11,311,641 and 11,583,607, which describe animal bioprotein scaffold wound dressings. The other authors have no conflicts of interest with respect to the research, authorship, or publication of this article. No funding was received from any agencies in the public, commercial, or not-for-profit sectors.

ACKNOWLEDGMENT

The authors thank Sofregen Medical for the contribution of Seri Surgical Scaffold used in the study.

PHOTOGRAPHIC CONSENT

Author Daniel S. Rouhani, BS, provided written informed consent for the use of his image.

REFERENCES

- Akopov A, Artioukh DY, Molnar TF. Surgical staplers: the history of conception and adoption. *Ann Thorac Surg*. 2021;112:1716–1721.
- Saber A. Ancient Egyptian surgical heritage. *J Invest Surg*. 2010;23:327–334.
- Dhivya S, Padma VV, Santhini E. Wound dressings: a review. *Biomedicine (Taipei)* 2015;5:22.
- Kim J, Shin Y. Medical adhesive-related skin injury associated with surgical wound dressing among spinal surgery patients: a cross-sectional study. *Int J Environ Res Public Health* 2021;18:9150.
- McNichol L, Lund C, Rosen T, Gray M. Medical adhesives and patient safety: state of the science: consensus statements for the assessment, prevention, and treatment of adhesive-related skin injuries. *J Wound Ostomy Continence Nurs*. 2013;40:365–380; quiz E1.
- Ousey K, Wasek S. Clinician perspectives on medical adhesive-related skin injuries. *Wounds UK*. 2016;12:42–46.
- Chalmers BP, Melugin HP, Sculco PK, et al. Characterizing the diagnosis and treatment of allergic contact dermatitis to 2-octyl cyanoacrylate used for skin closure in elective orthopedic surgery. *J Arthroplasty* 2017;32:3742–3747.
- Michalowicz A, Comrie R, Nicholas C, Wagner M, Kehoe J. Wound complications after 2-octyl skin closure systems for total joint arthroplasty. *J Bone Jt Infect*. 2020;5:101–105.
- Pate RC, Neumeister MW. Severe wound complication due to Prineo surgical dressing in shoulder hemiarthroplasty: a case report. *JBJS Case Connect*. 2020;10:e0306.
- Fumarola S, Allaway R, Callaghan R, et al. Overlooked and underestimated: medical adhesive-related skin injuries. *J Wound Care* 2020;29:S1–S24.
- Swanson S, Bashmail R, Fellin CR, et al. Prototype development of a temperature-sensitive high-adhesion medical tape to reduce medical-adhesive-related skin injury and improve quality of care. *Int J Mol Sci*. 2022;23:7164.
- Zabaglo M, Sharman T. Postoperative wound infection. *StatPearls*. Orlando, FL: StatPearls Publishing LLC; 2023.
- Lefèvre-Utile A, Braun C, Haftek M, Aubin F. Five functional aspects of the epidermal barrier. *Int J Mol Sci*. 2021;22:11676.
- Seidelman JL, Mantyh CR, Anderson DJ. Surgical-site infection prevention: a review. *JAMA* 2023;329:244–252.
- Hou Y, Collinsworth A, Hasa F, Griffin L. Incidence and impact of surgical-site infections on length of stay and cost of care for patients undergoing open procedures. *Surg Open Sci*. 2023;11:1–18.
- Dumville JC, Gray TA, Walter CJ, et al. Dressings for the prevention of surgical-site infection. *Cochrane Database Syst Rev*. 2016;12:CD003091.
- Clancy CM. SCIP: making complications of surgery exception rather than the rule. *AORN J*. 2008;87:621–624.
- Bratzler DW, Houck PM; Surgical Infection Prevention Guideline Writers Workgroup. Antimicrobial prophylaxis for surgery: an advisory statement from the National Surgical Infection Prevention Project. *Am J Surg*. 2005;189:395–404.
- Bratzler DW, Hunt DR. The Surgical Infection Prevention and Surgical Care Improvement Projects: national initiatives to improve outcomes for patients having surgery. *Clin Infect Dis*. 2006;43:322–330.
- Bucciarelli A, Motta A. Use of Bombyx mori silk fibroin in tissue engineering: From cocoons to medical devices, challenges, and future perspectives. *Biomaterials Adv*. 2022;139:212982.
- Cao Y, Liu F, Chen Y, et al. Drug release from core-shell PVA/silk fibroin nanoparticles fabricated by one-step electrospinning. *Sci Rep*. 2017;7:11913.
- Mazurek L, Szudzik M, Rybka M, Konop M. Silk fibroin biomaterials and their beneficial role in skin wound healing. *Biomolecules* 2022;12:1852.
- Thurber AE, Omenetto FG, Kaplan DL. In vivo bioresponses to silk proteins. *Biomaterials* 2015;71:145–157.
- Madden PW, Klyubin I, Ahearne MJ. Silk fibroin safety in the eye: a review that highlights a concern. *BMJ Open Ophthalmol*. 2020;5:e000510.
- Wani SUD, Veerabhadrapa GH. Silk fibroin based drug delivery applications: promises and challenges. *Curr Drug Targets* 2018;19:1177–1190.
- Sun W, Gregory DA, Tomeh MA, Zhao X. Silk fibroin as a functional biomaterial for tissue engineering. *Int J Mol Sci*. 2021;22.
- Kundu B, Rajkhowa R, Kundu SC, Wang X. Silk fibroin biomaterials for tissue regenerations. *Adv Drug Deliv Rev*. 2013;65:457–470.
- Nguyen TP, Nguyen QV, Nguyen VH, et al. Silk fibroin-based biomaterials for biomedical applications: a review. *Polymers (Basel)* 2019;11:1933.
- Rouhani DS, Singh NK, Chao JJ, et al. Silk bioprotein as a novel surgical-site wound dressing: a prospective, randomized, single-blinded, superiority clinical trial. *Aesthet Surg J Open Forum* 2023;5:ojad071.
- Fonacier L, Bernstein DI, Pacheco K, et al.; American Academy of Allergy, Asthma & Immunology. Contact dermatitis: a practice parameter: update 2015. *J Allergy Clin Immunol Pract*. 2015;3:S1–39.
- Farris MK, Petty M, Hamilton J, Walters S-A, Flynn MA. Medical adhesive-related skin injury prevalence among

- adult acute care patients: a single-center observational study. *J Wound Ostomy Continence Nurs.* 2015;42:589–598.
32. Keist C. Rayon and its impact on the fashion industry at its introduction, 1910-1924. Iowa State University; 2009. Available at: <https://dr.lib.iastate.edu/entities/publication/7e38ee32-7198-44d0-9b3f-d4089b6a45f5>. Accessed July 14, 2023.
 33. How everyday products make people sick: toxins at home and in the workplace. *JAMA* 2007;298:807–812.
 34. Gupta BS. Manufacture, types and properties of biotextiles for medical applications. In: King MW, Gupta BS, Guidoin R, eds. *Biotextiles as Medical Implants*. Sawston, UK: Woodhead Publishing; 2013:3–47.
 35. Davis PJ. How might we achieve oxygen balance in wounds? *Int Wound J.* 2007;4:18–24.
 36. Cole M, Smith I, Vlad SC, Golenbock SW, Sorrentino K. The effect of a skin barrier film on the incidence of dressing-related skin blisters after spine surgery. *AORN J.* 2020;112:39–48.
 37. Mendes ISF, Prates A, Evtuguin DV. Production of rayon fibres from cellulosic pulps: State of the art and current developments. *Carbohydr Polym.* 2021;273:118466.
 38. Heichel DL, Vy NCH, Ward SP, Adamson DH, Burke KA. Controlled radical polymerization of hydrophilic and zwitterionic brush-like polymers from silk fibroin surfaces. *J Mater Chem B.* 2020;8:10392–10406.
 39. Mandrekas A, Zambacos G, Anastasopoulos A, Hapsas D. Reduction mammoplasty with the inferior pedicle technique: early and late complications in 371 patients. *Br J Plast Surg.* 1996;49:442–446.
 40. Kreithen J, Caffee H, Rosenberg J, et al. A Comparison of the LeJour and Wise pattern methods of breast reduction. *Ann Plast Surg.* 2005;54:236–241; discussion 241.
 41. Cunningham BL, Gear AJ, Kerrigan CL, Collins ED. Analysis of breast reduction complications derived from the BRAVO study. *Plast Reconstr Surg.* 2005;115:1597–1604.
 42. Davis GM, Ringler SL, Short K, Sherrick D, Bengtson BP. Reduction mammoplasty: long-term efficacy, morbidity, and patient satisfaction. *Plast Reconstr Surg.* 1995;96:1106–1110.
 43. Guo P, Du P, Zhao P, et al. Regulating the mechanics of silk fibroin scaffolds promotes wound vascularization. *Biochem Biophys Res Commun.* 2021;574:78–84.
 44. Zhang Y, Lu L, Chen Y, et al. Polydopamine modification of silk fibroin membranes significantly promotes their wound healing effect. *Biomater Sci.* 2019;7:5232–5237.
 45. Hodgkinson T, Yuan XF, Bayat A. Electrospun silk fibroin fiber diameter influences in vitro dermal fibroblast behavior and promotes healing of ex vivo wound models. *J Tissue Eng.* 2014;5:2041731414551661.
 46. Zhang W, Chen L, Chen J, et al. Silk fibroin biomaterial shows safe and effective wound healing in animal models and a randomized controlled clinical trial. *Adv Healthc Mater.* 2017;6.
 47. Park YR, Sultan MT, Park HJ, et al. NF- κ B signaling is key in the wound healing processes of silk fibroin. *Acta Biomater.* 2018;67:183–195.
 48. Olczyk P, Komosinska-Vashev K, Wisowski G, Mencner L, Stojko J, Kozma EM. Propolis modulates fibronectin expression in the matrix of thermal injury. *Biomed Res Int.* 2014;2014:748101.
 49. Bao P, Kodra A, Tomic-Canic M, Golinko MS, Ehrlich HP, Brem H. The role of vascular endothelial growth factor in wound healing. *J Surg Res.* 2009;153:347–358.
 50. Ju HW, Lee OJ, Lee JM, et al. Wound healing effect of electrospun silk fibroin nanomatrix in burn-model. *Int J Biol Macromol.* 2016;85:29–39.
 51. Guan Y, Sun F, Zhang X, et al. Silk fibroin hydrogel promote burn wound healing through regulating TLN1 expression and affecting cell adhesion and migration. *J Mater Sci Mater Med.* 2020;31:48.
 52. Li X, Liu Y, Zhang J, You R, Qu J, Li M. Functionalized silk fibroin dressing with topical bioactive insulin release for accelerated chronic wound healing. *Mater Sci Eng C Mater Biol Appl.* 2017;72:394–404.
 53. Yang P, Wang D, Shi Y, et al. Insulin-containing wound dressing promotes diabetic wound healing through stabilizing HIF-1 α . *Front Bioeng Biotechnol.* 2020;8:592833.